

## Structural Feature-Based Detection of Glaucoma from Retinal Fundus Images Using Medical Image Processing Techniques\

Dr. Salim Al-Harthy<sup>1\*</sup>, Dr. Maryam Al-Rawahi<sup>1</sup>

<sup>1</sup>Sultan Qaboos University College of Medicine and Health Sciences, Department of Ophthalmology and Clinical Imaging Research, Muscat, Oman

---

### ABSTRACT

Glaucoma and Diabetic retinopathy are the two major eye diseases that affect human eye. Irreversible damage and partial loss of vision is caused by these diseases if not treated at the earliest. Glaucoma is a painless neurological disease in which fluid pressure in the eye increases constantly, which damages the optic nerve and thereby affects the sight of the patient. It is considered as the one of important reason for blindness. Conventional screening methods enable us to identify these diseases only after it has caused partial damage (25% or more) to the eye. Detection of glaucoma at the earliest stages using computational decision support systems can help overcome this problem. Highly specific quantitative information of the Optic Nerve Head (ONH) or optic disc (OD) and other retinal structures can be obtained using funduscopy. This paper proposes the detection of glaucoma using structural features extracted from retinal fundus images. The optic cup to disc ratio, rim to disc ratio and cup shape analysis are used as parameters for identifying the symptoms of glaucoma from the fundus image. The extracted features are fed to Support Vector Machine classifier, with which an accuracy of 80% is obtained.

**KEYWORDS:** Glaucoma, Optic disc, Optic cup, Neuro Retinal Rim, Cup to Disc Ratio, Rim to Disc Ratio.

---

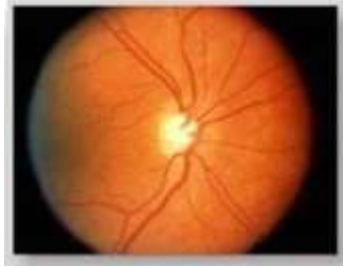### 1. INTRODUCTION

Glaucoma is a painless neurological disease. This disease is hard to diagnose especially in the early stages due to a very slow progression rate. The World Health Organization (WHO) has labelled it as the second most important cause of blindness worldwide.[1] There is a huge increment in glaucoma patients every year. Glaucoma is a group of eye diseases that have common conducts such as increased intraocular pressure, damage to optic nerve head, gradual vision loss and ultimately blindness. Glaucoma diagnosis is solely a clinical diagnosis since it cannot be detected with blood or definite genetic test.[2]

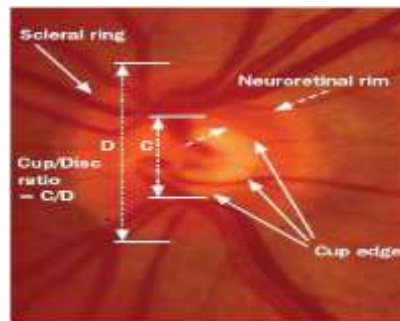
Diagnosis in the early period is very crucial to prevent blindness; therefore, regular screening of patient can aid in diagnosing disease at an early and treatable stage. One way to detect glaucoma is through periodic examinations. To conduct these screenings, specialized equipment is necessary, such as Optical Coherence Tomography (OCT) and Heidelberg Retinal Tomography (HRT). Existing pre-diagnosis is expensive and time consuming; hence, computer-aided diagnosis (CAD) of glaucoma may become a game changer in coming years. The CAD is simple, repetitive, exceptionally fast in the diagnosis and immune from inter- and intra-observer variability. The CAD involves the analysis of digital images of fundus of the eye and can be very useful in developing countries where there is a scarcity of ophthalmologist as it can bring the clinician to the level of an expert observer.

Funduscopy is capable of capturing objective, accurate and precise quantitative information about optic nerve head (ONH) or optic disc (OD) and other retinal structures. Fundus camera is a specialized low power microscope attached with an attached camera. In a retinal fundus image as shown in fig. 1, the ONH is an overall brighter and rounded area, and there is a smaller, rounded and brightest area inside the ONH called a cup. ONH is a point on the retina where the optic nerve leaves the eye. Visual information is transmitted to the brain via the

fibres present in the optic nerve. In this method the ophthalmologist will have to identify through the digital images of fundus of the eye and inform whether the retinal image is glaucomatous or non-glaucomatous.



*Fig. 1: Retinal fundus image*



*Fig.2: ROI showing disc and cup region*

The objective of this work is the detection of glaucoma from retinal fundus images using structural features. The steps involved are: acquisition of image database, extraction of Region Of Interest (ROI), pre-processing of segmented fundus image, structural feature extraction and classification.

The outline of the paper is as follows. Section 2 gives precise detail of proposed methodology and imaging database. Section 3 explains different structural features involved. Section 4 describes the classification. Results obtained are given in section 5. The paper concludes in Section 6.


## 2. PROPOSED METHODOLOGY

Structural features are those features that are based on the appearance of the image such as colour, size, shape etc. ROI is the region containing the optic disc. Preprocessing is done to remove noise and artifacts. In segmentation, a threshold-based method is used to segment the optic disc and optic cup. Extraction of structural features obtained from the retinal fundus image is proposed. Classification is the final stage in which the input image is classified as normal or glaucomatous. Also, overall accuracy of the system is computed.

## 3. METHODOLOGY

### Preprocessing

Fundus image has been preprocessed before structural feature extraction. Spatial resolution has been improved using bilinear interpolation technique. The purpose of pre-processing is to cater images acquired from various fundus camera having different resolutions. In the pre-processing stage, all input images are scaled and region of interest of size 200\*250 containing OD is cropped. Histogram equalization technique has been employed to increase the contrast of cropped image. Fig. 1 shows the enhanced (Enh) image after pre-processing.



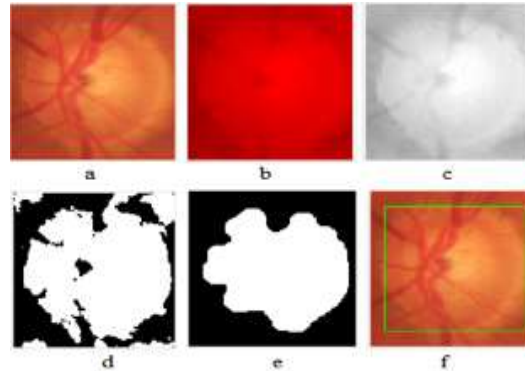
*Fig. 3. Enh image after preprocessing. (a) Enh image, (b) Red channel of Enh image, (c) Green channel of Enh image, (d) Blue channel of Enh image*

### Segmentation

Figure 4 shows the block diagram of optic disc and cup segmentation.

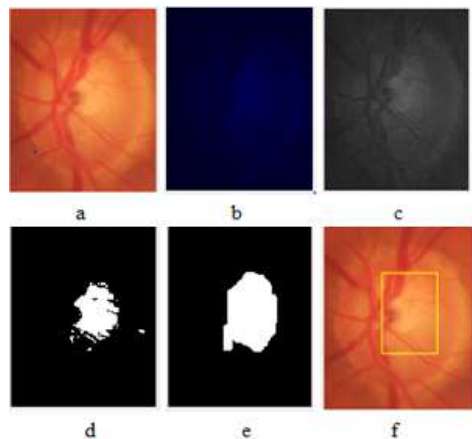
*Disk segmentation:* Red channel gives maximum visibility of disc, which makes it the most appropriate channel for disc segmentation. In disc segmentation process, the binary image is obtained after thresholding red channel. Otsu global thresholding is applied to binarize the image and to extract approximate disc shape from the initial

image. The imperfections present in the binary image after thresholding has been removed using morphological opening. After morphological opening all small objects creating noise around OD are eliminated, and it also makes disc boundary smooth. Also, all those large noisy objects with an area smaller than 2000 pixels have been further removed. Convex hull is applied to smoothen the disc boundary. By performing the above steps pure optical disk is obtained. 'Bounding box' has been used to compute the vertical diameter of the disk. Fig.2 illustrates this process.[2]



**Fig. 4. Disk segmentation. (a) Enh image, (b) Red channel of Enh image, (c) Grey scale image, (d) Thresholding, (e) Morphological opening, (f) vertical disk diameter**

**Cup segmentation:**For cup segmentation, blue channel of enhanced image has been used. Blue channel generated the maximum visualisation of the cup. In blue channel, most of the blood vessels automatically merge into cup area, making it most suitable for error free cup segmentation. In cup segmentation process, the binary image is obtained after thresholding blue channel. After morphological closing, all small objects creating noise around cup are removed, and it also makes cup boundary smooth. After morphological closing, all connected objects smaller than 5000 pixels have been removed. Morphological closing using a large circular structuring element has been used to combine all remaining bright pixels into the single cup area. Convex hull is applied and pure cup region is obtained. 'Bounding box' has been used to compute the vertical diameter of the cup. Fig.3 shows the result of various steps and the intermediate results included in this procedure.[2]



**Fig. 5. Binary image obtained during cup segmentation (a)Enh image, (b) Blue channel of Enh image, (c) Grey scale image (d) Thresholding blue channel, (e) Morphological closing, (f) Vertical cup diameter**

### Feature extraction

The extraction of attributes aims to describe the images according to the extracted features. These features are used for pattern recognition. Depending on the purpose of the problem, feature extraction can return distinct features to a same image. Structural features are based on the factors such as colour, size, shape of the image. Cup to disc ratio, rim to disc ratio and Hausdroff dimension of the cup are the derived features. [2]

**Cup to Disc Ratio (CDR):**Degeneration of nerve fibres and excavation of cup region to disc region causes 'cupping' in glaucomatous eyes. In otherwords, enlargement of cup region is said to occur in glaucoma. CDR is Ratio of Cup Vertical Diameter (CVD) to Disc Vertical Diameter (DVD). Vertical diameters are obtained by applying bounding box on the segmented disc and cup image. It is observed that  $CDR < 0.4$  for normal eyes and  $CDR > 0.4$  for glaucomatous eyes. [3]

$$CDR = \frac{CVD}{DVD}$$

*Rim to Disc Ratio(RDR):* Neuro Retinal Rim (NRR) is the area between cup and disc boundary that contains axons of nerve fibre. In glaucoma, the degeneration of fibre nerves imposes rim size to decrease. Vertical NRR (VNRR), which is the thickness of superior part of rim only is the most affected rim region. Hence, VNRR is computed. The difference of upper y-coordinates of cup and disc bounding box gives VNRR. It is found that the value of RDR > 0.25 for normal eyes and RDR < 0.25 for glaucoma.[4]

$$RDR = \frac{VNRR}{DVD}$$

*Cup shape analysis:* Fractal analysis can be used as a measure of regularity of the contour of medical images. Change in cup shape is an early indication of glaucoma. It is due to the movement of blood vessels. As a consequence, glaucomatous eyes has a regular cup contour whereas normal eyes has irregular cup contour. In the proposed system, Hausdroff dimension is used to find the fractal dimension for the analysys of cup shape.

Hausdroff dimension is given by the equation:

$$D_o = \lim_{\epsilon \rightarrow 0} \frac{\log(N(\epsilon))}{\log \epsilon^{-1}}$$

The steps involved in computing the hausdroffs dimension are as follows:

- Cup contours are obtained by the erosion of extracted cup and then subtraction of eroded cup from the initially extracted cup area.
- Pad the segmented cup contour image with background pixels.
- Set the box size  $\epsilon$  to the size of the image.
- Compute  $N(\epsilon)$ , which corresponds to the number of boxes of size  $\epsilon$  which contains at least one object pixel.
- If  $e > 1$  then  $e = e/2$  and repeat step 3.
- Compute the points  $\log(N(\epsilon)) * \log(1/\epsilon)$ , where  $N(\epsilon)$  is the number of hypercubes with dimension  $E$  and length  $\epsilon$  that fills that object.
- Use the least squares method to fit a line to the points.
- The returned Hausdorff's fractal dimension (D) is the slope of the line.

The Hausdroff Dimension (D) for Normal eyes is  $1.11 < D < 1.15$  and for glaucoma is  $1.16 < D < 1.25$ . [2]

#### 4. CLASSIFICATION

Support Vector Machines are supervised machine learning technique that looks at data and sort it into one of the two categories from past trained labelled data. SVM can efficiently handle multi-dimensional data, binary classification and robustness added with help of different kernels. It is defined by a separating hyperplane. There exist many hyper planes that separate the two classes. The distance between two support hyper planes is called margin. SVM maximizes the margin of each hyperplane until it hit the training points. The optimal hyper plane is chosen as the one with maximum margin. The structural features extracted forms a vector, which is fed as the inputs to the SVM classifier.

#### 5. RESULTS

**Dataset:** The proposed system has been tested on REFUGE (Retinal Fundus Glaucoma Challenge) database consisting of 400 labelled images. It consist of 360 normal images and 40 glaucomatous images. Each image is having a resolution of 2124 x 2956 pixels.

The neuro-retinal rim (NRR) is the area between cup and disc boundary that contains axons of fibre nerve. In glaucoma, the degeneration of fibre nerves imposes rim size to decrease. The first fibre nerves effected by glaucoma are in the superior and inferior region of NRR. As a consequence, CDR value is increased in glaucoma eye and RDR value is decreased simultaneously. Irregular cup shape in normal eyes result in

Hausdroffs dimension in the range 1.11 and 1.15. Glaucoma eyes has regular cup contour shape and Hausdroffs dimension lies in the range 1.16 and 1.25. An accuracy of 86.7 % is obtained by applying SVM classifier.

## 6. CONCLUSION

In this paper, optic disc and optic cup are firstly segmented and then structural features are extracted from the retinal fundus images. Structural features help to clearly distinguish between healthy and glaucomatous eyes and hence a combination of CDR, RDR and cup shape analysis using Hausdroffs dimension has been used for classification. The features extracted forms a vector, which serves as input to the classifier. Classification is the final process in testing stage in which a decision is made determining whether the testing image falls into the class of normal or glaucoma. SVM classifier is applied and an accuracy of 86.7% is achieved.

## REFERENCES

- [1] World Health Organization: 'Prevention of Blindness and Visual Impairment'. Available at <http://www.who.int/blindness/causes/priority/en/>, accessed April2016
- [2] Khalil,T., Akram, M. U., Khalid, S., & Jameel, A. (2017). Improved automated detection of glaucoma from fundus image using hybrid structural and textural features. IET Image Processing, 11(9), 693-700.
- [3] Manju K, & Sabeenian RS (2017) . Robust CDR calculation for glaucoma identification. Biomedical Research 2017 , Vol.2, No.3.
- [4] Fauzia Khan, Shoaib A. Khan, Ubaid Ullah Yasin (2013). Detection of Glaucoma Using Retinal FundusImages. The 2013 Biomedical Engineering International Conference (BMEiCON-2013)

## CITE AN ARTICLE

It will get done by IJESRT Team